



[J Lasers Med Sci](#). 2018 Winter; 9(1): 11–14.

PMCID: PMC5775948

Published online 2017 Dec 26. doi: [10.15171/jlms.2018.03](https://doi.org/10.15171/jlms.2018.03)

PMID: [29399304](https://pubmed.ncbi.nlm.nih.gov/29399304/)

The Effect of Photobiomodulation on the Depth of Anesthesia During Endodontic Treatment of Teeth With Symptomatic Irreversible Pulpitis (Double Blind Randomized Clinical Trial)

[Sholeh Ghabraei](#),¹ [Nasim Chiniforush](#),² [Behnam Bolhari](#),¹ [Mohsen Aminsobhani](#),¹ and [Abbas Khosravi](#)^{1,*}

¹Department of Endodontic, School of Dentistry, Tehran University of Medical Sciences, Tehran, Iran

²Laser Research Center of Dentistry, Dentistry Research Institute, Tehran University of Medical Sciences, Tehran, Iran

***Correspondence to** Abbas Khosravi, Department of Endodontic, School of Dentistry, Tehran University of Medical Sciences, Tehran, Iran. Tel: +98 2188994824; Fax: +98 2188986688; abbaskhosravi45@yahoo.com

[Copyright](#) © 2018 J Lasers Med Sci

Abstract

Introduction: Achieving appropriate anesthesia in patients with symptomatic irreversible pulpitis in mandibular molars during endodontic treatment is always one of the most challenging aspects. Photobiomodulation (PBM) has been used in dentistry due to its anti-inflammatory properties and regenerative effects. This study evaluates the effects of PBM in the depth of anesthesia in inferior alveolar nerve block.

Methods: In this randomized clinical trial, 44 patients requiring endodontic treatment in lower molar, left or right were selected, half of them were randomly treated with PBM therapy. Laser irradiation by 980 nm diode laser with a single dose (15 J/cm², for 20 seconds) before anesthesia was performed at the buccal aspect. Inferior alveolar nerve block was performed once. Success was defined as no or mild pain (no need for any supplemental injection), based on the visual analogue scale during access cavity preparation. Results were evaluated using SPSS software.

Results: The results of this study showed that the necessity for supplemental injection was lower in the group receiving laser than in the group without laser ($P = 0.033$). The mean pain intensity during dentin cutting was lower in the group receiving laser than in the group without laser ($P = 0.031$). Also, the mean pain intensity during pulp dropping was lower in the group receiving laser, than the group without laser ($P = 0.021$).

Conclusion: Based on the results of this study, it seems that the application of PBM before anesthesia is effective on increasing depth of anesthesia.

Keywords: Photobiomodulation, Anesthesia, Pain, Endodontic therapy, Molar teeth

Introduction

Achieving appropriate anesthesia in mandibular molar teeth with irreversible pulpitis is one of the most challenging aspects of root canal treatment.¹ It is more complicated in teeth with symptomatic irreversible pulpitis.² Inferior alveolar nerve block is not profoundly successful in mandibular teeth

with symptomatic irreversible pulpitis and sometimes supplemental techniques are necessary.³

Nowadays photobiomodulation (PBM) is considered as an adjunct in anesthesia, the addition of gallium-aluminum-arsenide laser irradiation to intravenous regional anesthesia is safe, and reduces pain during and after the operation.⁴

The most local anesthetics in dentistry block sodium channels. Tetrodotoxin resistance sodium channels are resistant to local anesthetics and sensitized by prostaglandins.⁵

PBM has been used in dentistry for its anti-inflammatory,⁶ regeneration⁷ and analgesic⁴ properties. It can prevent nerve impulse conduction. Studies have shown that laser irradiation prevents axonal transmission of signals in nerve fibers A-delta and C, since nociceptive signals are transmitted by the fibers of to the spinal cord, it is likely that laser radiation reduces the transmission and subsequently reduces the feeling of pain.⁸ PBM effectiveness was shown in reducing pain after root canal therapy,⁹ but it hasn't been used as an adjunct in anesthesia in dentistry.

Some PBM applications in dentistry include the following:

To control pain, swelling and inflammation after surgery thus reducing the need for medication.¹⁰

To reduce pain after tooth fillings or dentin cutting with an inhibitory effect on the pulp nervous system.¹¹

The anti-inflammatory mechanism of PBM and its clinical use in physiotherapy.¹²

To reduce pain and swelling after implantation and accelerates bone formation around it.¹³

E) To reduce pain during orthodontic treatment and accelerate tooth movement, to accelerate bone destruction and bone formation together.¹⁴

F) To reduce neuralgia, facial pain or pain caused by muscle spasms and temporomandibular joint disorders.¹⁵

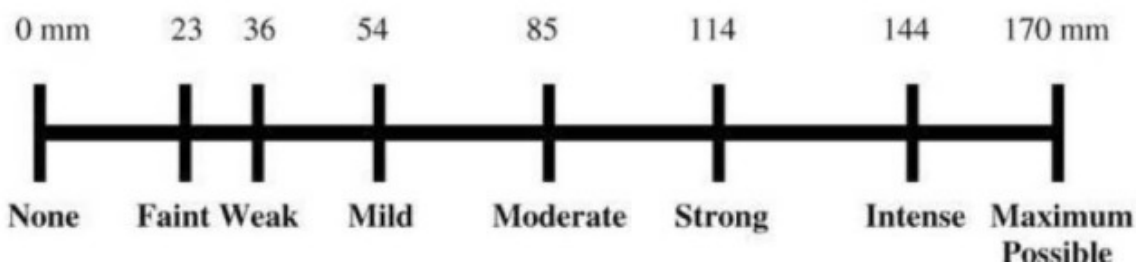
G) To reduce pain of dentinal hypersensitivity by inhibiting the nerve flow stimulating pain.¹⁶

It seems that the properties of PBM might be helpful in increasing the depth of anesthesia. The aim of this study was to evaluate the effect of PBM on the depth of anesthesia during endodontic treatment of lower mandibular molar with symptomatic irreversible pulpitis.

Methods

In this double blind randomized clinical trial, 44 patients needing root canal treatment in mandibular molars with irreversible pulpitis, prolonged response to cold test and positive response to electric pulp test¹⁷ as well as history of spontaneous pain with visual analog scale (VAS) 114 and above in the Heft-Parker VAS assessment, were evaluated ([Figure 1](#)). A sample of 22 patients was evaluated based on a previous study.¹¹

Place a mark on the line below to show the amount of pain that you feel.



[Figure 1](#)

VAS Score Used in This Study.

Exclusion Criteria

Systemic diseases such as heart disease, diabetes, cancer, mental illness or a pace maker; signs of lesion at apex of the tooth, pain and infection, and the use of antibiotics during the last week and pain killer over the last 24 hours. Malocclusion patients with painful lesions in another area in the mouth, amalgam and crown restoration, were excluded from the study.

Inclusion Criteria

Irreversible pulpitis confirmed by thermal tests and history of spontaneous pain, VAS form understanding, patient access, patient satisfaction, having over 18 years of age and no major medical condition.

At the beginning of the study, the goals were explained to the patients and written consent was obtained from them. The patients were asked to mark VAS forms on based on pain intensity before treatment (VAS0), during dentin cutting (VAS1) and pulp dropping (VAS2). VAS as a ruler is graded from zero to 170 with zero meaning painless and 170 meaning that the patient experienced the most imaginable pain. In this study, the concept of pain was explained to the patients and it was asked of them to mark based on the description on the line at points representing their pain. The samples were divided randomly into two groups. In half of them, a diode laser, Gallium:Aluminium:Arсениde 980 nm wavelength, 15 J/cm² (Simpler, doctor smile, Italy), was irradiated (continuous mode) with a low level laser tip for 20 seconds in the crowns of lower molars at the buccal aspect near the gingival margin immediately before anesthesia was performed. Teeth of the second group received placebo treatment (Device was switched off) and the operator was also unaware of the irradiation. For safety, during the procedures both practitioner and patients wore glasses. Inferior alveolar nerve block direct (conventional)¹⁸ method was performed at standard location with gauge 27 (Technofar, Italy), lidocaine hydrochloride 2% and 1/80000 epinephrine (Daroopaksh, Iran). Numbness of the lip was the criterion for anesthesia. VAS were recorded in both groups before beginning of treatment (VAS0), during cavity access preparation (dentin cutting VAS1) and at entry into the pulp (VAS2). Success was achieved if patients experienced mild pain or no pain (NO. PAIN -MILD. PAIN) during the preparation of the access cavity (score ≤54 in VAS) ([Figure 1](#)). In other words, there was no need for supplemental injection. If patients experienced moderate to severe pain during access cavity preparation (dentin

cutting) and entry to pulp, anesthesia failure was recorded and the necessary measures were taken to inject supplemental anesthetic (articaine 4% epinephrine 1/200000 EXIR) for infiltration or intrapulpal. The collected data was analyzed using the SPSS software version 19.

Results

Forty-four patients requiring endodontic treatment of molars teeth in down mandible, right or left were chosen and were randomly divided into 2 groups. 86.4% of the examined population were female and the remaining were male, which were divided evenly into 2 groups of laser and control. Sex of under study patients in both groups are presented in [Table 1](#). Also, Table 2 shows the percentage of teeth in both groups.

Table 1

Under Study Population by Sex

Variable	Groups		Total
	Female	Male	
Group under the laser	19 (86.4%)	3 (13.6%)	22 (100%)
Placebo group	19 (86.4%)	3 (13.6%)	22 (100%)
Total	38	6	44

Table 2

The Percentage of Teeth in Both Groups

Groups	Variable					Total
	No. of teeth n = 36	No. of teeth n = 37	No. of teeth n = 46	No. of teeth n = 47	No. of teeth n = 48	
Group receiving laser, No. (%)	7 (31.8%)	3 (13.6%)	5 (22.7%)	6 (27.3%)	1 (4.5%)	22 (100%)
Placebo group, No. (%)	6 (27.3%)	4 (18.02%)	7 (31.8%)	5 (22.7%)	0 (0%)	22 (100%)
Total, No. (%)	13 (29.5%)	7 (15.9%)	12 (27.3%)	11 (25%)	1 (2.3%)	44 (100%)

The necessity for supplemental injection (both articaine infiltration and intrapulpal) was lower in the group receiving laser than in the placebo group and this difference was statistically significant ($P = 0.033$). The results showed that the mean pain intensity in VAS1 (dentin cutting) in the laser receiving

group was lower than in the group that did not receive laser and this difference was statistically significant ($P = 0.031$; [Table 3](#)).

Table 3

Comparison of the mean \pm standard deviation, pain at VAS 0, VAS1 in Laser or Placebo Groups

	Lased	Number	Mean \pm SD	P Value
VAS 0	Yes	22	133.09 \pm 14.77	0.55
	No	22	130.36 \pm 15.29	
VAS1	Yes	22	43.55 \pm 46.35	0.031
	No	22	77.36 \pm 53.86	

The results of the study showed that 50% in the control group and 18.2% in the laser group received supplemental anesthesia during dentin cutting and the difference was statistically significant ($P = 0.026$; [Table 4](#)).

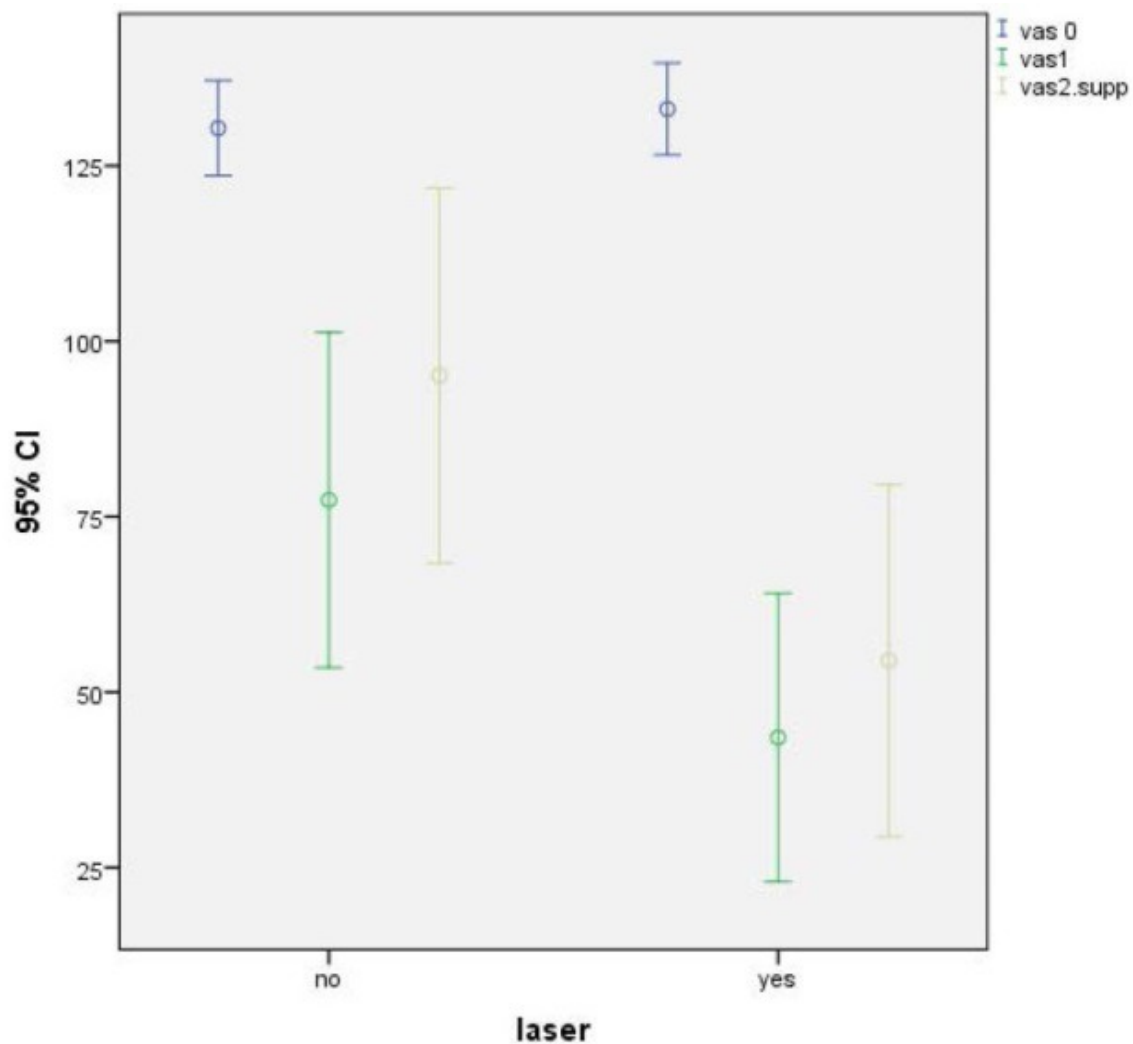
Table 4

Population Under Study That Received or Did not Receive Supplemental Anesthesia During Dentin Cutting

Groups	Variable		
	No supplemental anesthesia	Received supplemental anesthesia	Total
Group under the laser, No. (%)	18 (81.8)	4 (18.2)	22 (100)
Placebo group, No. (%)	11 (50)	11 (50)	22 (100)
Total, No. (%)	29 (65.9)	15 (34.1)	44 (100)

Based on Mann-Whitney test Mean \pm standard deviation, pain intensity in VAS2 (pulp entry) in the laser group was 54.5 \pm 56.6 and in the control group was 95.09 \pm 60.2. VAS2 average rating of pain intensity in the laser group was 18.48 and 26.52 in the control group which showed statistically significant difference ($P = 0.021$).

As shown in [Figure 2](#), in the group receiving laser with a 95% CI, intensity is lower than in the group that did not receive laser.



[Open in a separate window](#)

[Figure 2](#)

Comparison of Pain Intensity in the Group Receiving Laser.

Discussion

Effective anesthesia in endodontic treatment is important. Anesthesia in mandibular molar teeth with irreversible pulpitis is one of the most challenging aspects during root canal treatment.^{1,19}

Because of side effects and complications of intraosseous²⁰ and intraligamentary²¹ injections, other methods such as PBM therapy are offered. This study aimed to evaluate the effects of low power lasers to increase the depth of anesthesia.

It has been reported in some studies that Ga:Al:As provide clinical procedures with minimal patient discomfort and without any side effects.²²

Studies have shown pain relief by LLLT after surgical endodontic treatment²³ and in patients with temporomandibular joint pain, trigeminal neuralgia, myalgia, aphthae and hypersensitivity as well.²⁴

Common commercially available LLLT systems use semiconductor diode lasers. These are generally variants of either gallium:aluminium:arsenide which emit in the near infrared spectrum (700-940 nm).²⁵ In our study we used gallium:aluminium:arsenide laser for 20 seconds, 980 nm wavelength, 15 J/cm².

The results of this study showed that the mean pain intensity in VAS1 in the group receiving laser was lower than in the group that did not receive laser ($P = 0.031$). It was also found that the rate of receiving supplemental injection (both articaine infiltration and intrapulpal) in patients who had undergone laser before anesthesia were significantly lower than the control group ($P = 0.033$). It was also found that pain intensity in the group receiving laser, was lower than the group who did not receive it. Tanboga et al in a study of 10 children aged 6-9 years old used low power laser Er: YAG for the preparation of 20 teeth cavities. In Half of the patients, PBM was applied before starting work and the other half was not irradiated and finally it was observed that children had less pain in the laser group.¹¹ It has been reported in some studies that PBM can be effective in anesthesia and pain, the addition of gallium-aluminum-arsenide laser irradiation to intravenous regional anesthesia is safe, and reduces pain during and after the operation.⁴

The results of these 2 studies was in line with our study. It is natural that with increase numbness, need for supplemental anesthesia is reduced. It is suggested that with larger studies, application of lasers, their advantages and disadvantages be further investigated to ensure ease of use of dental lasers.

Conclusion

Based on the results of this study, it seems that the application of PBM before anesthesia is effective in reducing pain and supplemental injection during root canal therapy.

Conflict of Interests

All authors declare that they have no conflict of interest.

Ethical Considerations

The protocol of this study was approved by the Ethics committee of Tehran University of Medical Science, Tehran, Iran. Also, the study was registred in Iranian Registry of Clinical Trials website (identifier: IRCT2016112631102N1; <http://en.irct.ir/trial/24533>).

Notes

Please cite this article as follows: Ghabraei S, Chiniforush N, Bolhari B, Aminsobhani M, Khosarvi A. The effect of photobiomodulation on the depth of anesthesia during endodontic treatment of teeth with symptomatic irreversible pulpitis (double blind randomized clinical trial). J Lasers Med Sci. 2018;9(1):11-14. doi:10.15171/jlms.2018.03.

References

1. Parirokh M, Yosefi MH, Nakhaee N, Abbott PV, Manochehrifar H. The success rate of bupivacaine and lidocaine as anesthetic agents in inferior alveolar nerve block in teeth with irreversible pulpitis without spontaneous pain. Restor Dent Endod. 2015;40(2):155–160. doi: 10.5395/rde.2015.40.2.155. [[PMC free article](#)] [[PubMed](#)] [[CrossRef](#)] [[Google Scholar](#)]
2. Vreeland DL, Reader A, Beck M, Meyers W, Weaver J. An evaluation of volumes and concentrations of lidocaine in human inferior alveolar nerve block. J Endod. 1989;15(1):6–12. doi: 10.1016/s0099-2399(89)80091-3. [[PubMed](#)] [[CrossRef](#)] [[Google Scholar](#)]

3. Potocnik I, Bajrovic F. Failure of inferior alveolar nerve block in endodontics. *Endod Dent Traumatol.* 1999;15(6):247–251. [[PubMed](#)] [[Google Scholar](#)]
4. Nesioonpour S, Akhondzadeh R, Mokmeli S, Moosavi S, Mackie M, Naderan M. Does low-level laser therapy enhance the efficacy of intravenous regional anesthesia? *Pain Res Manag.* 2014;19(6):e154–158. [[PMC free article](#)] [[PubMed](#)] [[Google Scholar](#)]
5. Hargreaves KM, Berman LH. *Cohen's Pathways of the Pulp Expert Consult.* 11th ed. Elsevier Health Sciences; 2015.
6. de Morais NC, Barbosa AM, Vale ML. et al. Anti-inflammatory effect of low-level laser and light-emitting diode in zymosan-induced arthritis. *Photomed Laser Surg.* 2010;28(2):227–232. doi: 10.1089/pho.2008.2422. [[PubMed](#)] [[CrossRef](#)] [[Google Scholar](#)]
7. Kreisler M, Christoffers AB, Willershause B, d'Hoedt B. Effect of low-level GaAlAs laser irradiation on the proliferation rate of human periodontal ligament fibroblasts: an in vitro study. *J Clin Periodontol.* 2003;30(4):353–358. [[PubMed](#)] [[Google Scholar](#)]
8. Tsuchiya K, Kawatani M, Takeshige C, Matsumoto I. Laser irradiation abates neuronal responses to nociceptive stimulation of rat-paw skin. *Brain Res Bull.* 1994;34(4):369–374. [[PubMed](#)] [[Google Scholar](#)]
9. Asnaashari M, Mohebi S, Paymanpour P. Pain Reduction Using Low Level Laser Irradiation in Single-Visit Endodontic Treatment. *J Lasers Med Sci.* 2011;2(4):139–143. doi: 10.22037/2010.v2i4.2356. [[CrossRef](#)] [[Google Scholar](#)]
10. Ferrante M, Petrini M, Trentini P, Perfetti G, Spoto G. Effect of low-level laser therapy after extraction of impacted lower third molars. *Lasers Med Sci.* 2013;28(3):845–849. doi: 10.1007/s10103-012-1174-4. [[PubMed](#)] [[CrossRef](#)] [[Google Scholar](#)]
11. Tanboga I, Eren F, Altinok B, Peker S, Ertugral F. The effect of low level laser therapy on pain during dental tooth-cavity preparation in children. *Eur Arch Paediatr Dent.* 2011;12(2):93–95. [[PubMed](#)] [[Google Scholar](#)]
12. Bjordal JM, Lopes-Martins RAB, Joensen J, Iversen VV. The anti-inflammatory mechanism of low level laser therapy and its relevance for clinical use in physiotherapy. *Phys Ther Rev.* 2010;15(4):286–293. doi: 10.1179/1743288X10Y.0000000001. [[CrossRef](#)] [[Google Scholar](#)]
13. Sculean A, Schwarz F, Becker J. Anti-infective therapy with an Er:YAG laser: influence on peri-implant healing. *Expert Rev Med Devices.* 2005;2(3):267–276. doi: 10.1586/17434440.2.3.267. [[PubMed](#)] [[CrossRef](#)] [[Google Scholar](#)]
14. Youssef M, Ashkar S, Hamade E, Gutknecht N, Lampert F, Mir M. The effect of low-level laser therapy during orthodontic movement: a preliminary study. *Lasers Med Sci.* 2008;23(1):27–33. doi: 10.1007/s10103-007-0449-7. [[PubMed](#)] [[CrossRef](#)] [[Google Scholar](#)]
15. Falaki F, Nejat AH, Dalirsani Z. The Effect of Low-level Laser Therapy on Trigeminal Neuralgia: A Review of Literature. *J Dent Res Dent Clin Dent Prospects.* 2014;8(1):1–5. doi: 10.5681/joddd.2014.001. [[PMC free article](#)] [[PubMed](#)] [[CrossRef](#)] [[Google Scholar](#)]
16. Sgolastra F, Petrucci A, Severino M, Gatto R, Monaco A. Lasers for the treatment of dentin hypersensitivity: a meta-analysis. *J Dent Res.* 2013;92(6):492–499. [[PubMed](#)] [[Google Scholar](#)]
17. Moradi Askari E, Parirokh M, Nakhaee N, Hosseini HR, Abbott PV. The Effect of Maxillary First Molar Root Length on the Success Rate of Buccal Infiltration Anesthesia. *J Endod.* 2016;42(10):1462–1466. doi: 10.1016/j.joen.2016.07.005. [[PubMed](#)] [[CrossRef](#)] [[Google Scholar](#)]

18. Khalil H. A basic review on the inferior alveolar nerve block techniques. *Anesth Essays Res.* 2014;8(1):3–8. doi: 10.4103/0259-1162.128891. [[PMC free article](#)] [[PubMed](#)] [[CrossRef](#)] [[Google Scholar](#)]
19. Hargreaves KM, Keiser K. Local anesthetic failure in endodontics. *Endod Topics.* 2002;1(1):26–39. doi: 10.1034/j.1601-1546.2002.10103.x. [[CrossRef](#)] [[Google Scholar](#)]
20. Penarrocha-Oltra D, Ata-Ali J, Oltra-Moscardo MJ, Penarrocha-Diago M, Penarrocha M. Side effects and complications of intraosseous anesthesia and conventional oral anesthesia. *Med Oral Patol Oral Cir Bucal.* 2012;17(3):e430–434. [[PMC free article](#)] [[PubMed](#)] [[Google Scholar](#)]
21. Kaufman E, Galili D, Garfunkel AA. Intraligamentary anesthesia: a clinical study. *J Prosthet Dent.* 1983;49(3):337–339. [[PubMed](#)] [[Google Scholar](#)]
22. Elshenawy HM, Eldin AM, Abdelmonem MA. Clinical Assessment of the Efficiency of Low Level Laser Therapy in the Treatment of Oral Lichen Planus. *Open Access Maced J Med Sci.* 2015;3(4):717–721. doi: 10.3889/oamjms.2015.112. [[PMC free article](#)] [[PubMed](#)] [[CrossRef](#)] [[Google Scholar](#)]
23. Kreisler MB, Haj HA, Noroozi N, Willershausen B. Efficacy of low level laser therapy in reducing postoperative pain after endodontic surgery-- a randomized double blind clinical study. *Int J Oral Maxillofac Surg.* 2004;33(1):38–41. [[PubMed](#)] [[Google Scholar](#)]
24. Kulekcioglu S, Sivrioglu K, Ozcan O, Parlak M. Effectiveness of low-level laser therapy in temporomandibular disorder. *Scand J Rheumatol.* 2003;32(2):114–118. [[PubMed](#)] [[Google Scholar](#)]
25. Walsh LJ. The current status of low level laser therapy in dentistry Part 1 Soft tissue applications. *Aust Dent J.* 1997;42(4):247–254. [[PubMed](#)] [[Google Scholar](#)]

Articles from Journal of Lasers in Medical Sciences are provided here courtesy of **Shahid Beheshti University of Medical Sciences**