

COVID-19 is an emerging, rapidly evolving situation.

Get the latest public health information from CDC: <https://www.coronavirus.gov>.

Get the latest research from NIH: <https://www.nih.gov/coronavirus>.

COVID-19 is an emerging, rapidly evolving situation.

Get the latest public health information from CDC: <https://www.coronavirus.gov>.

Get the latest research from NIH: <https://www.nih.gov/coronavirus>.

FULL TEXT LINKS



Case Reports

> [Int J Environ Res Public Health](#), 16 (22) 2019 Nov 15

# Photobiomodulation Therapy in the Treatment of Oral Mucositis, Dysphagia, Oral Dryness, Taste Alteration, and Burning Mouth Sensation Due to Cancer Therapy: A Case Series

[Marwan El Mobadder](#)<sup>1</sup>, [Fadi Farhat](#)<sup>2</sup>, [Wassim El Mobadder](#)<sup>2</sup>, [Samir Nammour](#)<sup>1</sup>

Affiliations

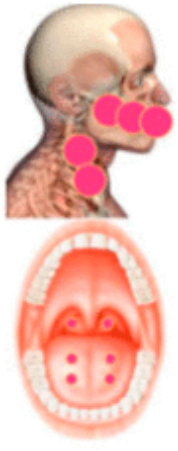
PMID: 31731594 PMCID: [PMC6888207](#) DOI: [10.3390/ijerph16224505](#)

## Abstract

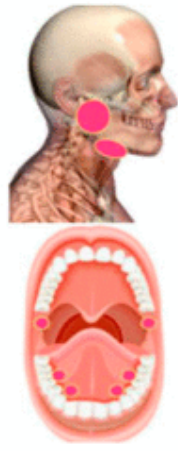Oral complications of cancer therapy, such as oral dryness, dysphagia, and taste alteration, are associated with a negative impact in the quality of life of the patients. Few supportive care measures are available for such complications. This case series reveals the effectiveness of the photobiomodulation (PBM) therapy when used in a specific protocol and parameters, in the management of oral complications related to cancer therapy. Dysphagia was measured using the functional outcome swallowing scale for staging oropharyngeal dysphagia (FOSS). Oral mucositis was measured according to the National Cancer Institute scale. The quantity of the whole resting and stimulated saliva was measured in order to assess the oral dryness. In addition, the taste alteration was measured according to a protocol suggested by the International Standards organization (ISO). Sensation of burning mouth was measured using a visual analogue scale. These measurements were made before treatment, during, and at the end of the treatment. Diode laser 635 nm was used in 3 J/cm<sup>2</sup>. Five sessions interleaved with 24 h breaks were conducted for the dysphagia and oral dryness, and 10 sessions were conducted for the taste alteration and burning mouth sensation. Regardless of the limitations of this case series, PBM can be considered safe, time saving, and a promising approach for the management of the oral complications due to cancer therapy and the quality of life of cancer patients.

**Keywords:** cancer complications; dysgeusia; dysphagia; oral dryness; supportive cancer care; taste alteration.

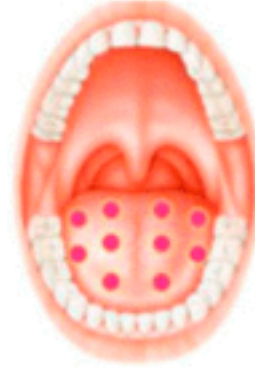# Figures



**Figure 1** 5  
Photobiomodulation  
(PBM) treatment area



**Figure 2** 5 PBM  
treatment area for the...



**Figure 3** 5 PBM  
treatment area for the...

## LinkOut – more resources

### Full Text Sources

[Europe PubMed Central](#)

[Multidisciplinary Digital Publishing Institute \(MDPI\)](#)

[PubMed Central](#)